

DIGESTION AND ABSORPTION

The branch of biology which deals with the study of life processes is called Human Physiology. Major human physiological processes are digestion and absorption, Exchange of gases, blood circulation, excretion, locomotion and movement, neural coordination, chemical coordination etc. Father of modern physiology is William Harvey.

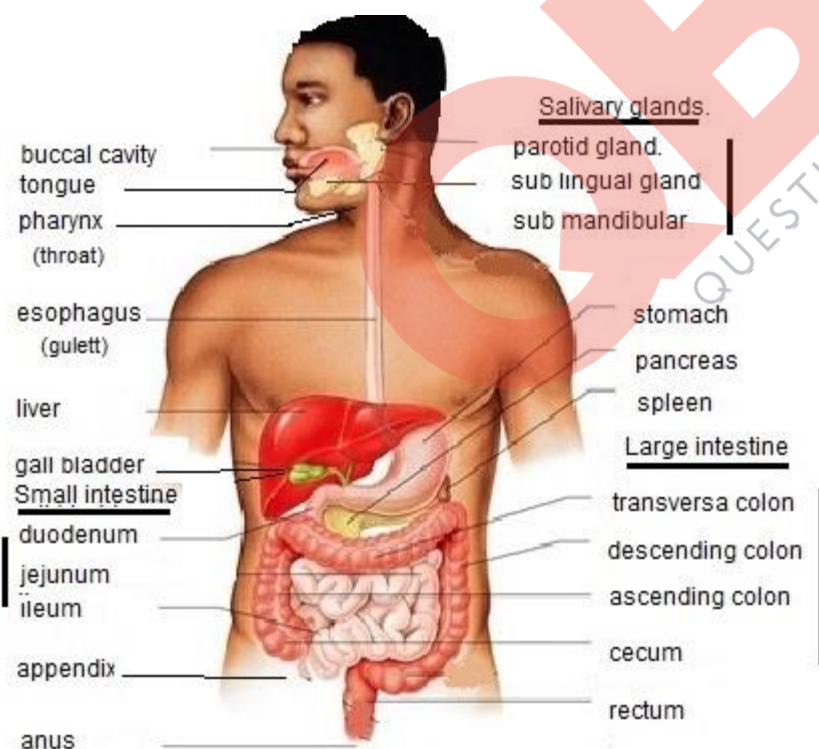
Food is the substance used for growth, maintenance and activities of an organism and it is a mixture of nutritive and nonnutritive substances. The nutrients are the chemical substances present in food. The physiological activity by which organisms obtain food from their environment is called nutrition.

Major components of food are carbohydrates, fats, proteins, minerals and vitamins. Water prevents dehydration of the body and plays an important role in metabolic processes.

The process of converting food materials into simple, soluble, and absorbable form is called digestion. The two processes coming under digestion are mechanical processes and bio chemical processes. Mechanical process includes the breaking down of complex food materials into simpler forms by physical means, such as cutting, tearing, crushing, chewing, pressing, rolling etc.

Biochemical process involves the breaking down of covalent bonds in the organic food molecules into simpler molecules by hydrolysis.

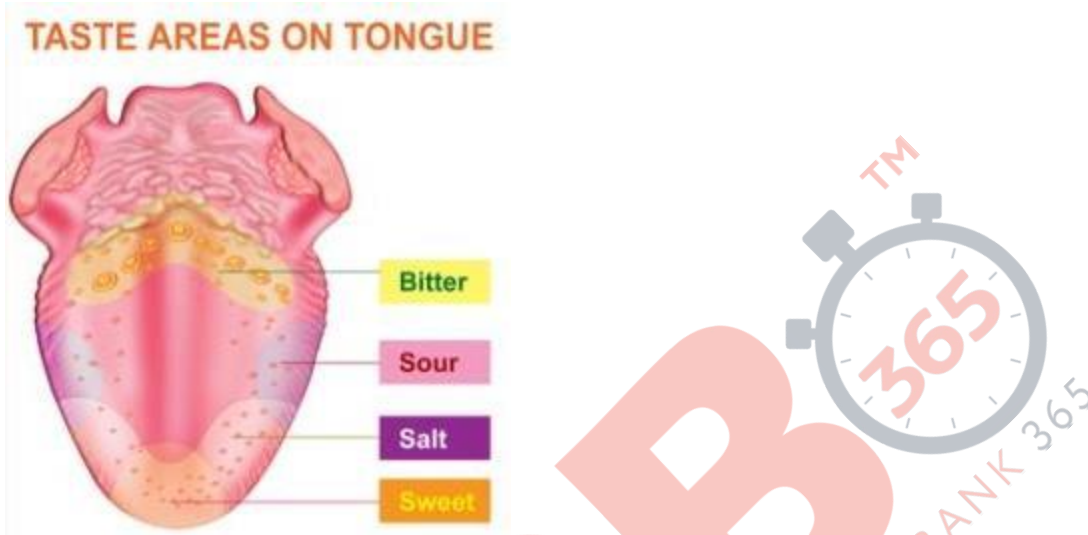
16.1 Digestive system: Human digestive system consist of a well developed alimentary canal, and associated glands.



16.1.1 Alimentary canal: It is a long coiled tube which is muscular and about 6m to 9 m in length extending from mouth to anus. It is lined by glandular epithelium and consist of a mouth, oral cavity or buccal cavity, pharynx, oesophagus, stomach, small intestine, large intestine, and anus. The major associated glands associated with the alimentary canal are salivary glands, gastric glands, liver, pancreas, gall bladder, and intestinal glands. All these organs are connected to the alimentary canal by a series of ducts.

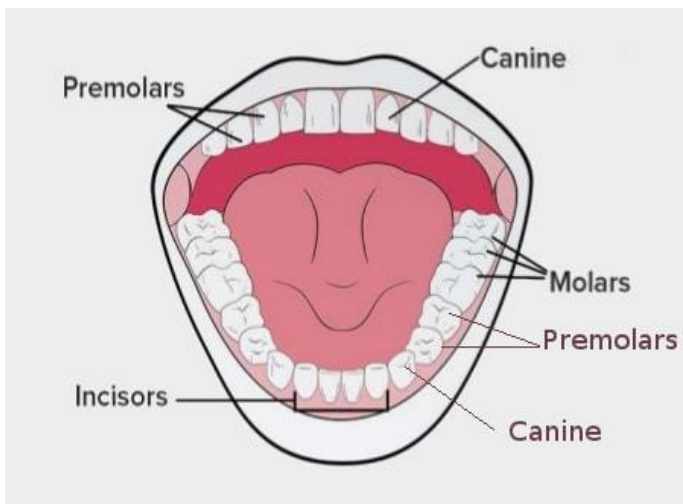
Mouth and Oral cavity: Mouth is a transverse slit like opening which is surrounded by two soft movable lips. Mouth leads into the oral cavity and its roof is called **palate**. Oral cavity is bordered internally by a pair of jaws called upper maxilla (upper jaw) and lower mandible (lower jaw) .The cheeks form the lateral walls of the oral cavity. At the hind end of the palate is a small finger shaped extension called uvula and the buccal cavity is lined by stratified squamous epithelium secreting mucous which lubricates the cavity.

A muscular tongue is situated on the floor of the oral cavity which is attached by a thin fold of frenulum. It helps in ingestion, chewing and swallowing of food materials and also bears taste buds for recognizing four types of tastes called sour, salt, bitter and sweet, in the indigested food materials. When moist food is in contact with these taste buds, we get the sensation of taste.



Teeth: The masticatory apparatus developed from specialized cells in the skin covering the jaw. The number, arrangement and shape of teeth is called dentition. The dentition in human is described as **thecodont, heterodont and diphyodont**. If teeth are found in cavities called teeth sockets off the upper and lower jaw bones, it is called **thecodont** dentition. In an adult human being there are 32 teeth, a row of 16 in each jaw.

There are four types of teeth based on their function. They are **Incisors, Canines, Premolars and Molars**. Having different types of teeth is called **heterodont** dentition.

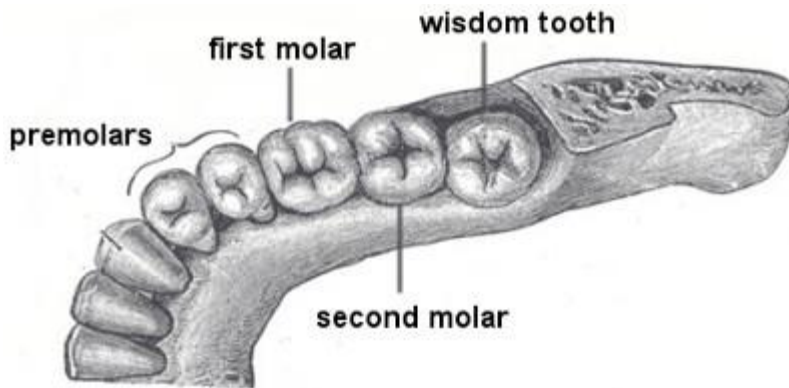


Incisors-Chisel shaped with sharp cutting edges used for cutting the food into pieces.

Canines-Dagger shaped and used for tearing the food.

Premolars and molars-Strong and have broad flat surfaces for crushing and grinding the food.

In man, the last four molars -2 in upper and 2 in lower jaw come out only after a person has reached the age of 17 or 18. These four molar teeth are called wisdom teeth.



Two sets of teeth appear in life time of man-Milk teeth and permanent teeth and are called **diphyodont** dentition.

Milk teeth are weak and temporary teeth developed in childhood. All premolars and molars are absent. Dentition consist of 20 teeth, 10 in each jaw. The number and arrangement of teeth on either side of each jaw is called dental formula. In adult man there are 16 teeth on each jaw.

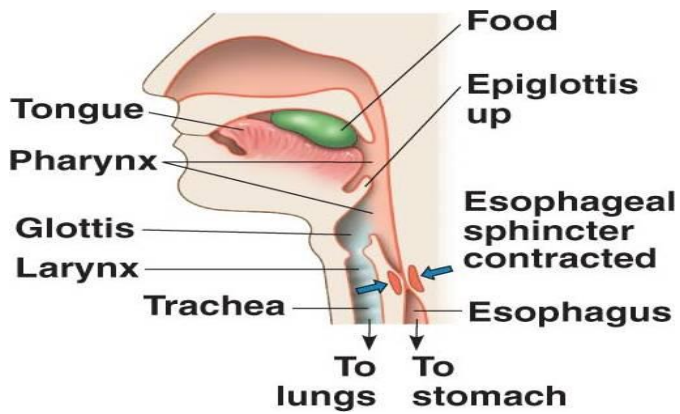
$$\mathbf{I - 2/2 \quad C - 1/1 \quad P - 2/2 \quad M - 3/3 = 16 \times 2 = 32}$$

The dental formula for milk dentition is

$$\mathbf{I - 2/2 \quad C - 1/1 \quad P - 0/0 \quad M - 2/2 = 10 \times 2 = 20}$$

The crown part of the tooth is covered by a non living white substance containing calcium salts called enamel. It is the hardest material in human body which forms the chewing surface of the tooth and is rich in calcium, phosphate and calcium carbonate. Due to the presence of teeth in the buccal cavity, mastication takes place in the buccal cavity.

Pharynx: It is a funnel shaped muscular passage common for both respiratory and digestive system. The buccal cavity leads to pharynx and the nasal cavity opens into it from above. It opens into oesophagus and trachea posteriorly. The opening of the pharynx into the trachea is the glottis and it is always kept open for respiration. A cartilaginous flap of skin called epiglottis cover the glottis and prevent the entry of food into the trachea while swallowing and uvula closes the opening into the nasal cavity.



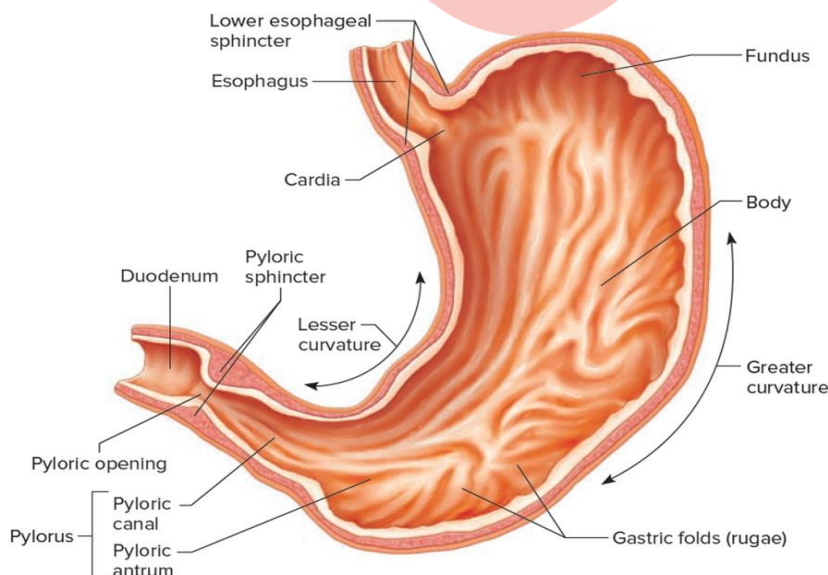
Oesophagus: Long muscular tube about 30 cm in length and connects the pharynx with the stomach. It passes through the neck, thorax and pierce the diaphragm (muscular partition wall which separates the thorax from the abdomen). The wave like contraction and relaxation of the muscular wall of oesophagus is called peristalsis. By the peristaltic movement of the walls of the oesophagus, food reaches the stomach. The gastro-oesophageal sphincter muscles controls the opening of oesophagus in the stomach.

Stomach: The widest part of the alimentary canal. It is located in the upper left region of the abdominal cavity. It is a large muscular bag just below the diaphragm which is C shaped. **The three regions of the stomach are fundus, cardiac and pylorus.**

The fundus is superior to the cardiac region. It is a temporary storage area which is filled with air that enters the stomach while swallowing. The oesophagus opens into the fundus.

Cardiac is the middle region where food is mainly stored.

Pylorus or antrum is the posterior narrow region which leads into the small intestine by an opening called pyloric orifice which is guarded by a ring shaped muscle called pyloric sphincter. When it relaxes, food material passes into the small intestine. Numerous gastric glands are present on the wall of the stomach which secrete gastric juice. When stomach is empty, its mucous membrane is thrown into numerous folding called **rugae** which project into the lumen of the stomach.



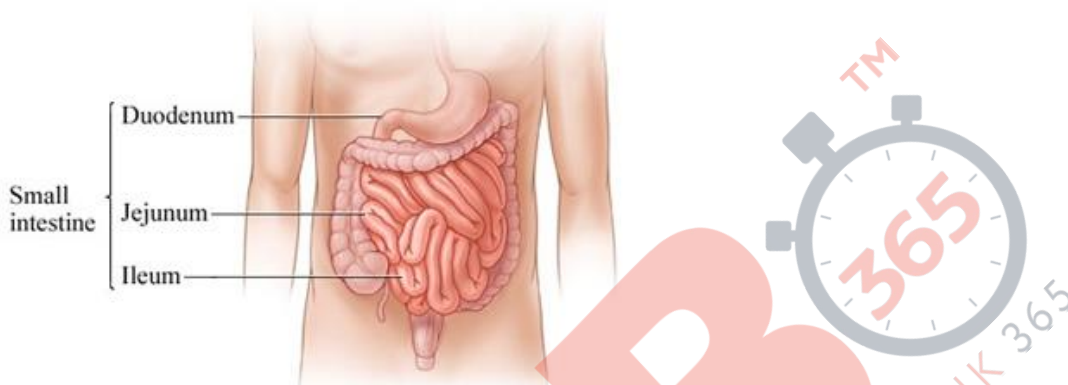
Small Intestine: Coiled, narrow, tubular and forms the longest part of the alimentary canal.

It is about 7 to 9 m in length and 2.4 cm in diameter. It lies in the abdomen. It is differentiated into duodenum, jejunum and ileum.

Duodenum: First part and is curved in the form of U. The liver and pancreas opens into the duodenum by a common duct.

Jejunum: Duodenum is followed by jejunum and is longer than duodenum.

Ileum: Last and longest part of small intestine. About 7m is length and 2 to 3 cm in diameter. Highly coiled and opens into large intestine in the lower right region of the abdominal cavity. The jejunum and ileum are often called the mesenteric part of small intestine. Major part of digestion and absorption takes place in small intestine.



Large intestine: Small intestine opens into large intestine. It is much shorter and wider than small intestine and 2 m in long. Differentiated into three regions- **Caecum, colon and rectum.**

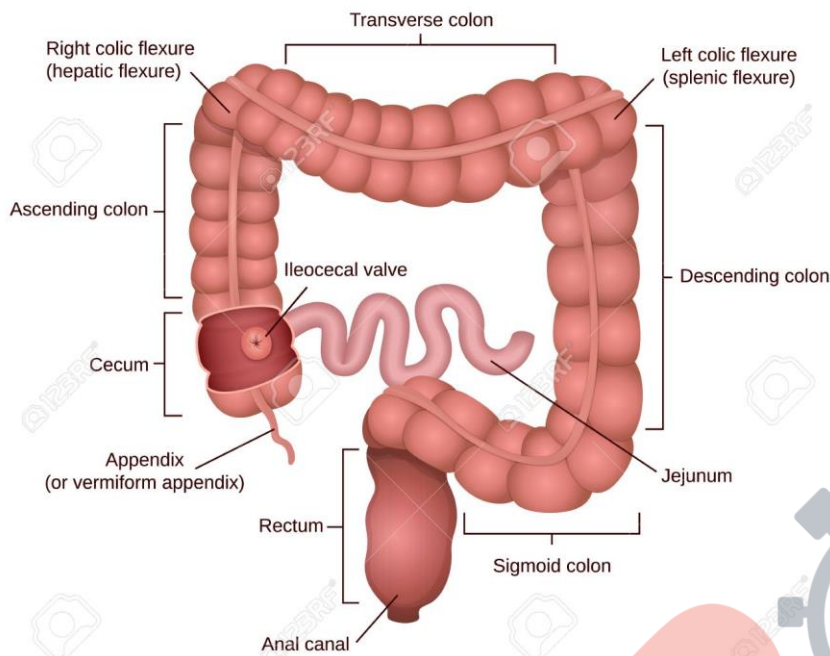
Caecum is very small pouch like in human and very large and spacious in horse and ass. A blind finger shaped process arising from the caecum is the vermiform appendix which is functionless organ in human and is called vestigial organ.

Colon is the largest part of large intestine.

Colon differentiated into ascending colon (running upwards), transverse colon (running across the abdomen) and descending colon (running downwards).

The descending colon is continued into the **rectum** .Rectum store the faeces temporarily and opens out through the anus. The anus is guarded by a voluntary sphincter muscle.

Structure of digestive organs



Histology of human alimentary canal: The wall of human alimentary canal from oesophagus to rectum is made up of 4 major layers-

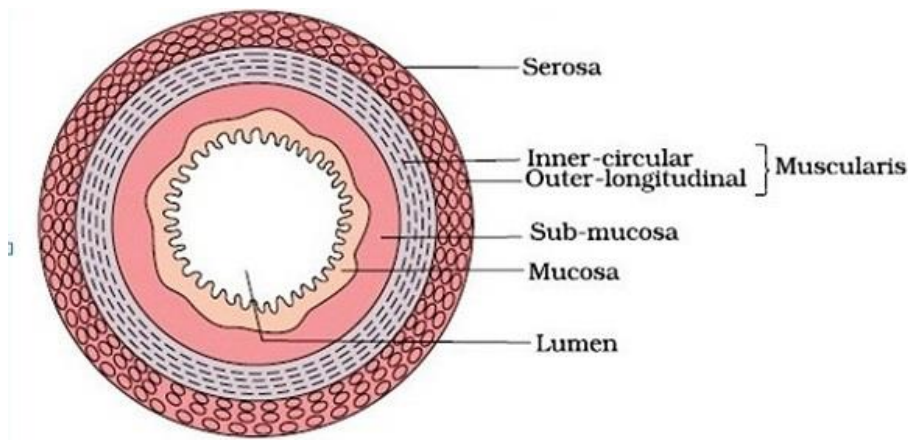
- **Serosa**
- **Muscularis**
- **Submucosa**
- **Mucosa.**

Serosa is the outermost layer of the alimentary canal and is a fibrous coat made up of thin mesothelium with some connective tissue.

Muscularis is seen outside the submucosa. Formed of an inner layer of circular muscles and an outer layer of longitudinal muscles. An oblique muscle layer may be seen in some regions.

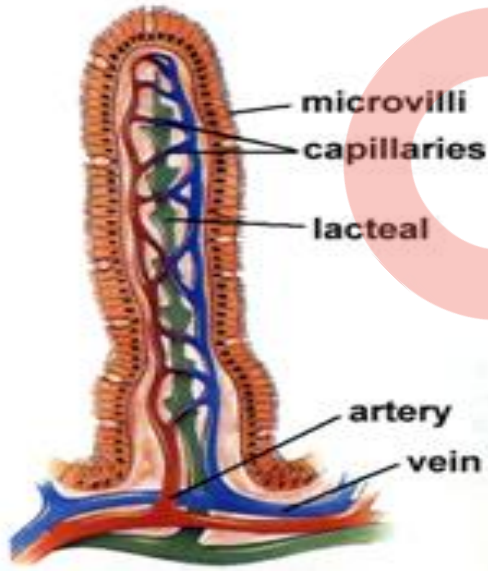
Submucosa: Seen just outside the mucosa. It is formed of loose connective tissue layer with blood vessel and lymph vessels. It is supplied with nerves. Duodenal glands are also seen in submucosa.

Mucosa: Innermost lining layer of the lumen of the alimentary canal. It has moist and friction resistant lining of epithelium. Secretory cells and absorptive cells are found in the epithelium. The goblet cells of the epithelium secrete mucous which function as lubricant and protects the epithelial surface from damage and digestion. When the stomach is empty, the mucosa and submucosa are thrown into large folds called **rugae**. It helps the stomach to stretch and folds disappear when the stomach is filled with food materials. The mucosa of the human small intestine has millions of microscopic finger like protections called villi.



Structure of the villi: Villi are the microscopic folds or the finger like projections found in the mucosa of the human small intestine. Each villus consist of network of blood capillaries, a net work of lymph vessels and an outer layer of columnar epithelial cells.

At the centre of each villus there is a large central lymph vessel called lacteal. Each epithelial cells of the villus has many as 2000 to 3000 short protoplasmic bristle like projections called microvilli or brush border. Villi increase the surface area of the intestinal mucosa and consequently help in enhancing the absorption of nutrients. The total surface area of small intestine is about 200 sq.m. The digested food is absorbed by the walls of the epithelial cells of the villi.



16.1.2 Digestive glands: The lands associated with the alimentary canal and help in digestion of food materials is called digestive glands. They are salivary glands, liver and pancreas.

Salivary glands: Digestive glands secrete saliva .Located in the oral cavity. In humans there are three pairs of salivary glands-

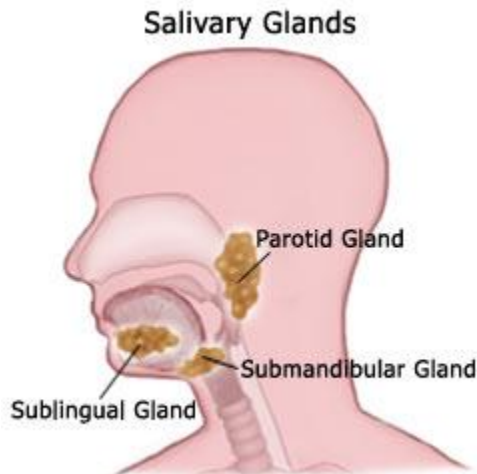
- Parotid glands
- Sublingual gland

- Submandibular or submaxillary glands.

Parotid glands are large and located just below and in front of ears.

Sublingual glands are found below the tongue on the floor of the mouth.

Submandibular glands or submaxillary glands lie below the angles of the lower jaw bone.



All these glands secrete saliva which reaches the oral cavity through their salivary ducts. Saliva is a clear watery fluid and man secretes about 1.5 litres of saliva per day. It is slightly alkaline and contains 99.5% of water and 0.5% residual substances which include digestive enzymes, mucin, electrolytes and inorganic salts. Saliva in man contains starch digesting enzymes called salivary amylase and an antimicrobial agent known as lysozyme. Salivary amylase digests starch and glycogen into maltose. It is absent in cow, buffalo, goat, tiger, lion etc. Saliva contains the electrolytes like Na^+ , K^+ , Cl^- , HCO_3^- which are derived from the blood plasma, mucous and serous fluid.

Functions of saliva are:

- Prevent the deteriorative processes in the oral cavity.
- Helps in washing away pathogenic bacteria.
- Thiocyanate ions and Proteolytic enzymes in the saliva can destroy bacteria.
- Protein antibodies in saliva are capable of destroying oral bacteria which cause dental caries.

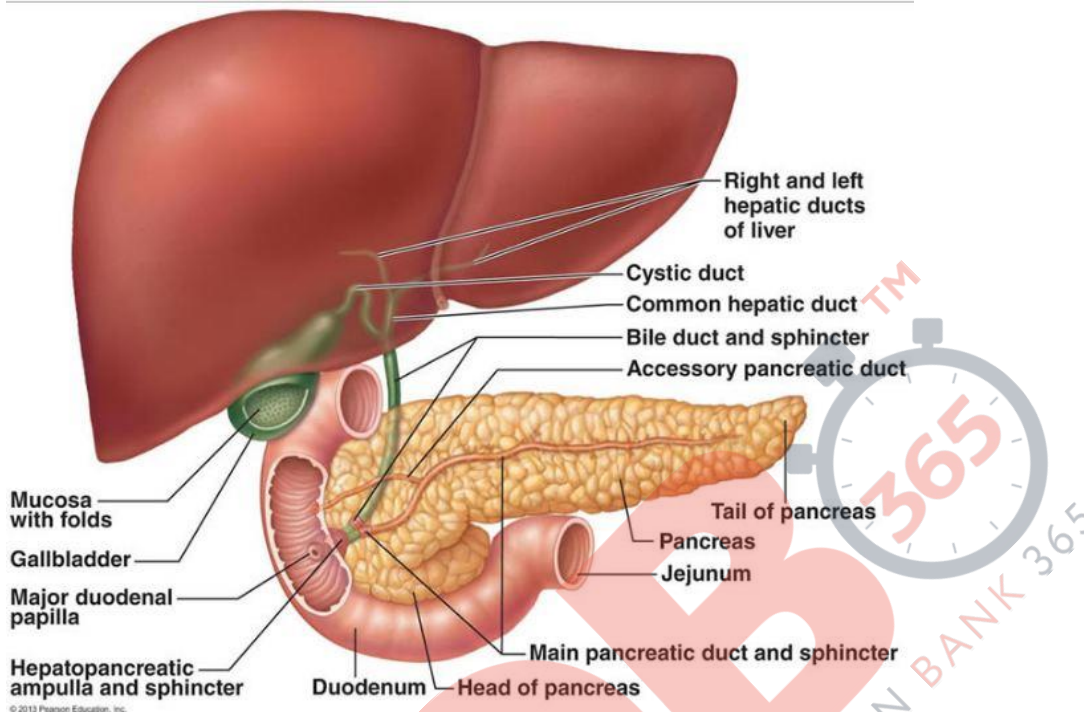
Liver: Largest gland in the human body. Weigh about 1.2 to 1.5Kg in adult man and has a dark chocolate colour. It is located in the right upper part of the abdomen just below the diaphragm. It is a bilobed gland with a small left lobe and a large right lobe. Lobules are the structural and functional unit of liver. Lobule is enclosed within a capsule called Glisson's capsule. Each lobule composed of Hepatic cells, Kupffers cells and blood filled spaces called sinusoids. Hepatic cells secrete bile and Kuppffer's cell digest bacteria, foreign particles, damaged blood cells etc.

Secretion of liver is bile which is alkaline, watery greenish fluid and it contains bile pigments, cholesterol, mucin, phospholipids, bile salts, and water. Two types of bile pigments- **Biliverdin and bilirubin**.

Biliverdin is a green pigment and bilirubin is a reddish yellow pigment.

Bile salts are sodium taurocholate and sodium glycocholate which helps in the digestion of fats and absorption of fat soluble vitamins A, D, E and K.

No enzymes are present in bile. Bile passes into the hepatic ducts. Cystic duct arises from the gall bladder. Hepatic and cystic duct join to form a common bile duct and joins with the pancreatic duct to form a common hepatopancreatic duct before opening into the duodenum. Sphincter which guards the common duct is **Sphincter of Oddi**.



Pancreas: It is an elongated digestive gland found in the bend of the duodenal loop and it is the second largest gland in the human body which is 12-15 cm long and has a reddish yellow colour. Pancreatic juice is the secretion of pancreas and it is a clear, watery, alkaline fluid rich in enzymes for digesting starch, lipids, proteins, and nucleic acids. It is released into pancreatic duct or Duct of Wirsung which joins with the common bile duct to form hepatopancreatic duct and it opens into the duodenal loop. Pancreas has two portions-Endocrine and exocrine part. Exocrine part is made up of glandular chambers called acini or alveoli which secrete alkaline pancreatic juice containing enzymes.

Endocrine part made up of scattered patches of cells called Islets of Langerhans which secrete the hormones- **insulin and glucagon**.

It is composed of three types of cells-

- Alpha cells-secrete glucagon
- Beta cells secrete insulin
- Delta cells secrete somatostatin.

16.2 Digestion of food: Digestion involve mechanical and chemical digestion.

Mechanical digestion: The breaking the food into smaller pieces physically through mastication, insalivation and by the peristaltic movement of the alimentary canal wall.

Chemical digestion: Saliva is secreted in mouth which gets mixed with food particles that digest it partly. The main components in saliva are mucin, lysozyme, thiocyanate and ptyalin which help in digestion.

Mucin is a glycoprotein that lubricates the food particles which in turn swallows the food.

Lysozyme is a bactericidal which kills the harmful bacteria. Ptyalin is present in the saliva digest the starch into maltose. Only 30% of starch is digested in the mouth.

Ptyalin is present in the human saliva, as the food consumed is mainly made up of starch. Ptyalin can digest only ripe and cooked starch while cannot digest the raw starch.

Teeth and tongue masticate, lubricate and adhere the food into bolus with the help of saliva and is conveyed into pharynx by swallowing or deglutination. Swallowing is a reflex action that, along with peristaltic wave, pushes the food down the different sections of the alimentary canal.

Bolus moves to the oesophagus and by the **peristaltic movement** of oesophagus food enters into the stomach through the gastro oesophageal sphincter.

Digestion in the stomach:

The digestion of food in the stomach is called gastric digestion. The insalivated bolus entering and filling the stomach stretches its walls, straightening the rugae. These walls now crush, knead and roll and churn the food which mixes the food thoroughly with the gastric juice secreted by the gastric glands.

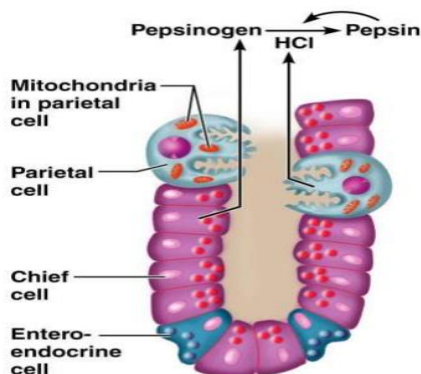
There are four types of cells which produce their secretion and spread it all over the inner region of the stomach:

Mucous neck cells or Goblet cells - They secrete the alkaline mucous for protecting the epithelium from hydrochloric acid. Mucous cells are found in the fundic, cardiac, and pyloric region of the stomach.

Parietal cells or oxyntic cells - Seen in the fundic, cardiac, and pyloric region. They secrete hydrochloric acid. Acidic medium is essential for the activation to release pepsin for protein digestion from the gastric glands. It kills micro-organisms entered along with the food.

Chief cells (Zymogenic cells or peptic cells) secrete pepsin and are located in the fundic region.

G cells –Located in the fundic, pyloric, and gastric region which secrete gastrin for the secretion of hydrochloric acid.



The secretion of gastric glands is collectively called gastric juices and they are acidic in reaction because it contains dilute HCl. About 99% of gastric juice is water and the remaining is formed of **pepsinogen, prorenin, gastric lipase, mucous, HCl, bicarbonates etc.**

Stomach stores food for 4 to 6 hours. The food after gastric digestion is acidic, semi digested and in a paste like form known as **chyme**. This passes little by little through the pyloric sphincter of the stomach into duodenum of small intestine.

The mucosal epithelium is protected and lubricated due to the presence of mucus and bicarbonates in the gastric juice. They protect the mucosal epithelium from damage by the highly concentrated HCl.

Digestion in the intestine: The chyme enters into the small intestine. Chyme in duodenum results in distension and it increases the osmotic pressure. The acidic chyme get neutralized by the bile secreted from the liver. It is followed by the alkaline part of the pancreatic juice and the mucus secretion by Brunners gland. Food gets mixed with bile, mucus and pancreatic juice enters into the jejunum and ileum and mix with the intestinal juice called succus entericus. Complete digestion occurs here due to the chemical action of various digestive enzymes in the intestinal juice and through the peristaltic and pendulous movement of the intestine.

Intestinal glands are of two types-Crypts of Lieberkuhn and Brunners gland.

Crypts of Lieberkuhn –These are the invaginations of the mucosa of the small intestine between the villi and they open at the base of the villi. They have three types of secreting cells-

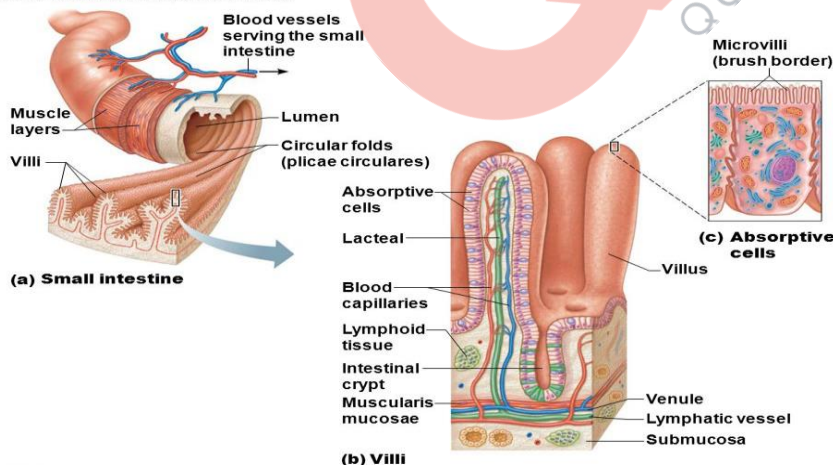
Goblet cells-secrete mucus

Paneth cells-secrete large number of digestive enzymes

Enterocytes- secrete water and electrolytes.

Brunners gland-Tubular glands found in the submucosa of the duodenum.

Figure 14.7 Structural modifications of the small intestine.



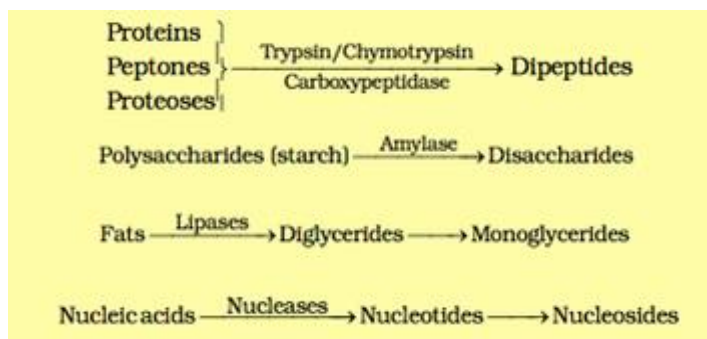
© 2015 Pearson Education, Inc.

They secrete a viscous, enzyme free, alkaline and watery fluid called mucoïd fluid which helps the duodenum to withstand the acidic chyme entering from the stomach until it is neutralized by the alkaline pancreatic juice and bile.

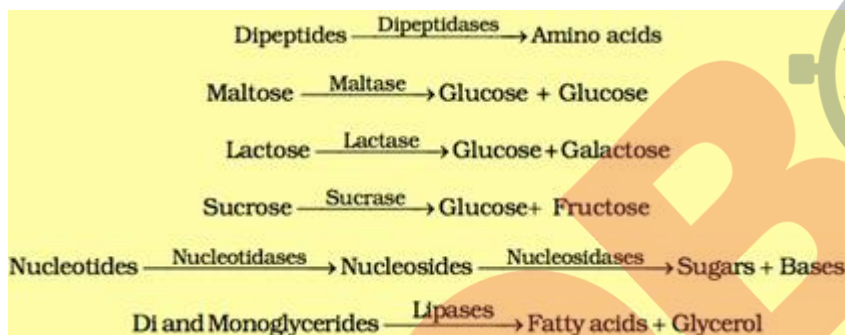
Secretion of both intestinal and Brunners gland are called **succus entericus** which is a slightly straw coloured alkaline fluid containing a number of enzymes, mucous and inorganic salts. The fully digested food after intestinal

digestion appears as a semifluid known as chyle. From the chyle the absorption of digested products of food occurs.

Action of pancreatic enzymes are



Intestinal enzymatic action are



Biomacromolecules are broken down in the duodenum and their absorption takes place in jejunum and ileum. Undigested food particles move into the large intestine through ileo-caecal valve.

Large

intestine:

In the large intestine water and minerals are absorbed and the walls secrete mucus for adhering and lubrication. The undigested food in the solid form called **faeces** are temporarily stored in the rectum and through the process of **defecation** it is thrown out of the body through the anus.

16.3 Absorption of digested food: The process by which the digested products and other nutrient molecules are taken into different cells or tissues from the alimentary canal is called absorption. The products of digestion are glucose, amino acids, fatty acids, glycerol, purines, pyrimidines, mineral salts, vitamins, water etc. The principal site for the absorption of digested food is the small intestine. Major part of the digested food is absorbed in the ileum of the small intestine. In the small intestine, the digested products are absorbed mainly through the microvilli of the absorptive cells. Large intestine also helps in the absorption of water.

Absorption of digested food takes place by passive absorption or active absorption or by facilitated transport mechanisms.

Simple diffusion- glucose, amino acids and some of electrolytes like chloride ions are absorbed by simple diffusion.

Facilitated diffusion for the absorption of fructose and some amino acids with the help of carrier ions like Na⁺.

Transport of water takes place based on the osmotic gradient.

Active transport is against the concentration gradient. So they need energy in the form of ATP. Amino acids, monosaccharides (glucose), electrolytes like Na^+ are absorbed by active transport. As fatty acids and glycerol are insoluble, they cannot be absorbed by blood. So they are first broken down into small droplets called micelles. Then it move into the intestinal mucosa. Then they are converted into small protein coated fat globules (Chylomicrons) and are carried to the lymph vessel in the villi. From there it reaches the blood stream. Absorption takes place in mouth, stomach, small intestine and large intestine. Maximum absorption is in the small intestine. Assimilation is the process by which the absorbed food reaches the various tissues through blood and utilizing them. The undigested food in the solid form (faeces) is stored in the rectum which initiates an efferent reflex causing an urge for the removal of faeces. The process of removal of faeces from the body is called defecation.

TABLE 16.1 The Summary of Absorption in Different Parts of Digestive System

Mouth	Stomach	Small Intestine	Large Intestine
Certain drugs coming in contact with the mucosa of mouth and lower side of the tongue are absorbed into the blood capillaries lining them.	Absorption of water, simple sugars, and alcohol etc. takes place.	Principal organ for absorption of nutrients. The digestion is completed here and the final products of digestion such as glucose, fructose, fatty acids, glycerol and amino acids are absorbed through the mucosa into the blood stream and lymph.	Absorption of water, some minerals and drugs takes place.

16.4 Disorders of the digestive system:

The intestinal tract is often inflamed by bacterial and viral infections. The infections are also caused by the parasites of the intestine such as tape worm, round worm, thread worm, hook worm, pin worm etc.

The common disorders of digestive system are jaundice, vomiting, diarrhea, constipation, indigestion etc.

1. Jaundice: A high level of bile pigments in the blood cause the skin, eyes, and mucous membrane appear yellow and this condition is called jaundice.

2. Vomiting: It is the ejection of stomach contents through mouth due to blockage of gut or reverse peristalsis. This vomiting reflex action is controlled by the vomit centre in the medulla oblongata. A feeling of nausea precedes vomiting.

3. Diarrhoea: If the absorption of water is not taking place properly, the faeces becomes watery and frequently discharged. The abnormal frequency of bowel movement and increased liquidity of the faecal discharge is called diarrhoea. It reduces the absorption of food.

4. Constipation: By the excessive absorption of water from the large intestine, the faecal matter becomes extremely dry and hard. The muscle of the colon of the large intestine becomes extremely dry and hard. The muscles of the colon of the large intestine become incapable of their normal peristaltic movements and remain contracted. As a result, the faeces is retained within the rectum and defecation occurs at prolonged intervals. This condition is called constipation. Constipation and diarrhoea are the conditions of irregular defecation. Constipation can be avoided by eating food with sufficient cellulose fibres.

5. Indigestion: It is the condition leading to a feeling of fullness due to improper digestion. The causes of indigestion are inadequate enzyme, secretion, anxiety, food poisoning, over eating, spicy food etc.

FAST TRACK REVISION:

Food is the substance used for growth, maintenance and activities of an organism and it is a mixture of nutritive and nonnutritive substances.

The process of converting food materials into simple, soluble, and absorbable form is called digestion.

Human digestive system consists of a well developed alimentary canal, and associated glands.

Alimentary canal is lined by glandular epithelium and consists of a mouth, oral cavity or buccal cavity, pharynx, oesophagus, stomach, small intestine, large intestine, and anus.

The dentition in human is described as thecodont, heterodont and diphyodont.

Pharynx is a funnel shaped muscular passage common for both respiratory and digestive system.

By the peristaltic movement of the walls of the oesophagus, the food enters into the stomach.

Stomach wall contains gastric glands which produce gastric juice.

Into the duodenum opens the duct from pancreas and liver.

Complete digestion of the food takes place by the intestinal juice succus entericus.

The walls of the large intestine absorb water and undigested food in the solid form reaches the rectum and excreted out through the anus.

The glands which are involved in digestion are salivary glands, liver and pancreas.